Git practical 2

- Prof Dr. Safaa Said
- Dr. Ahmed Alm

Liver –HX,E
(high power)

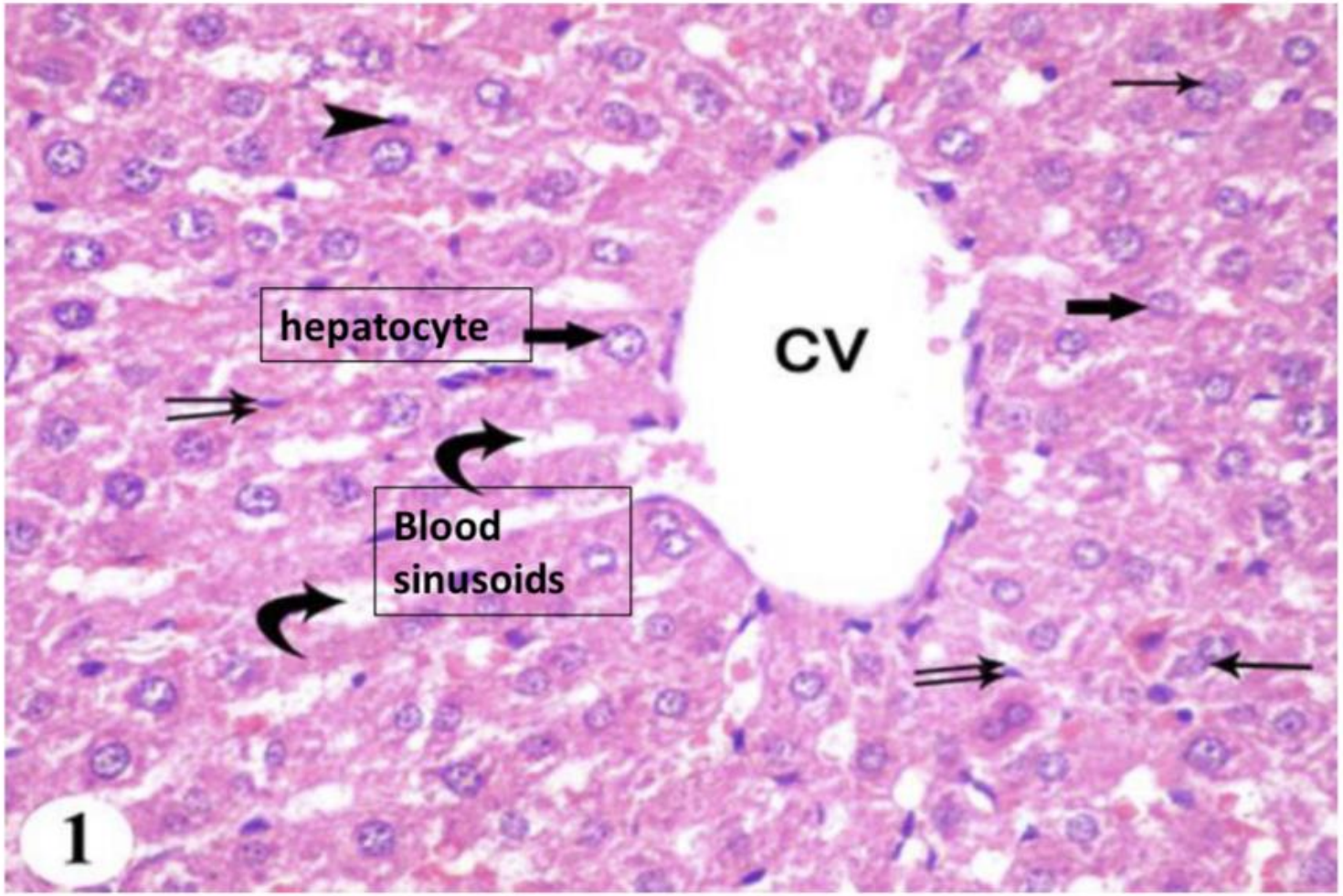

Liver
HX,E- low power

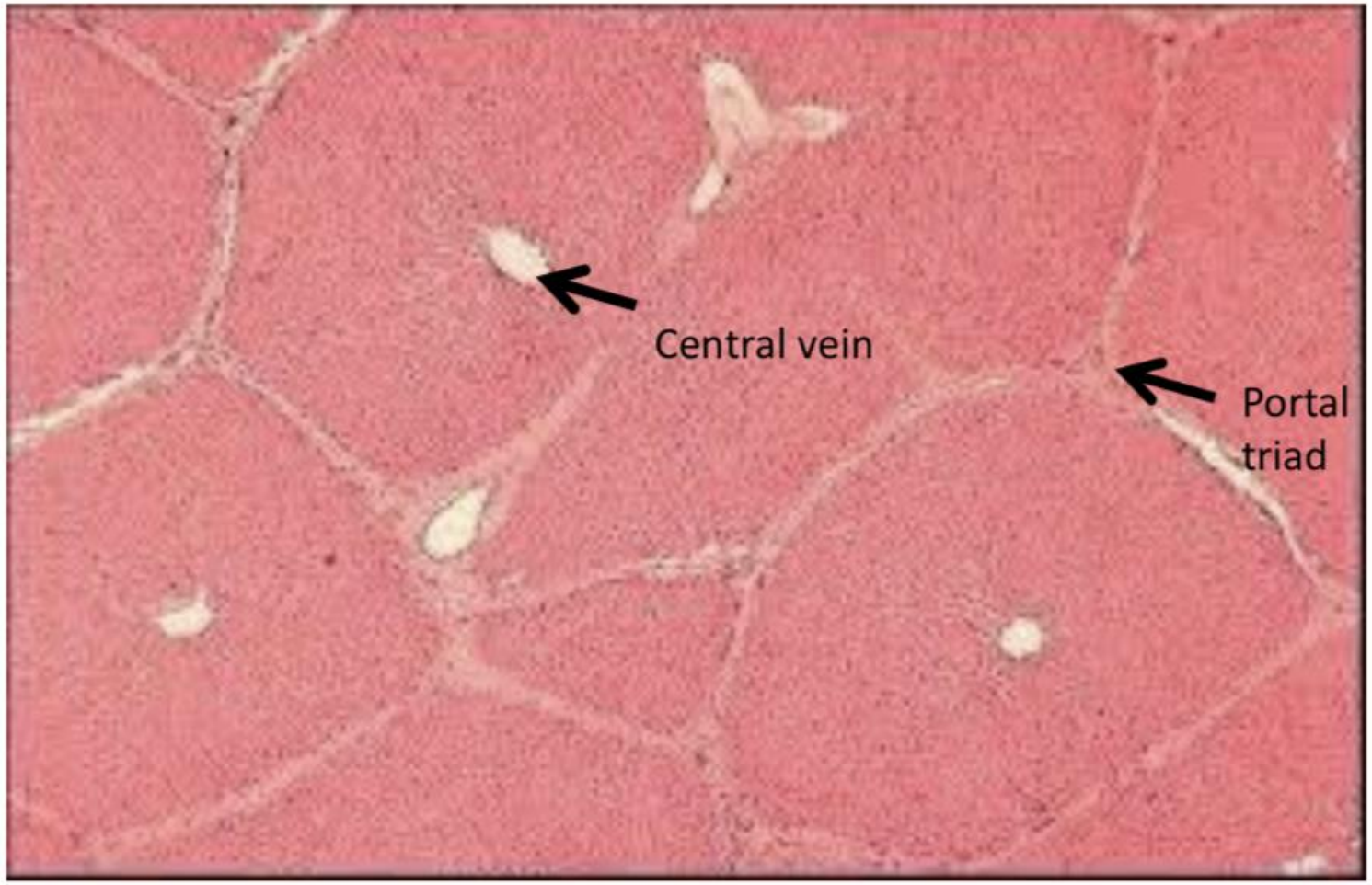

Pancreas

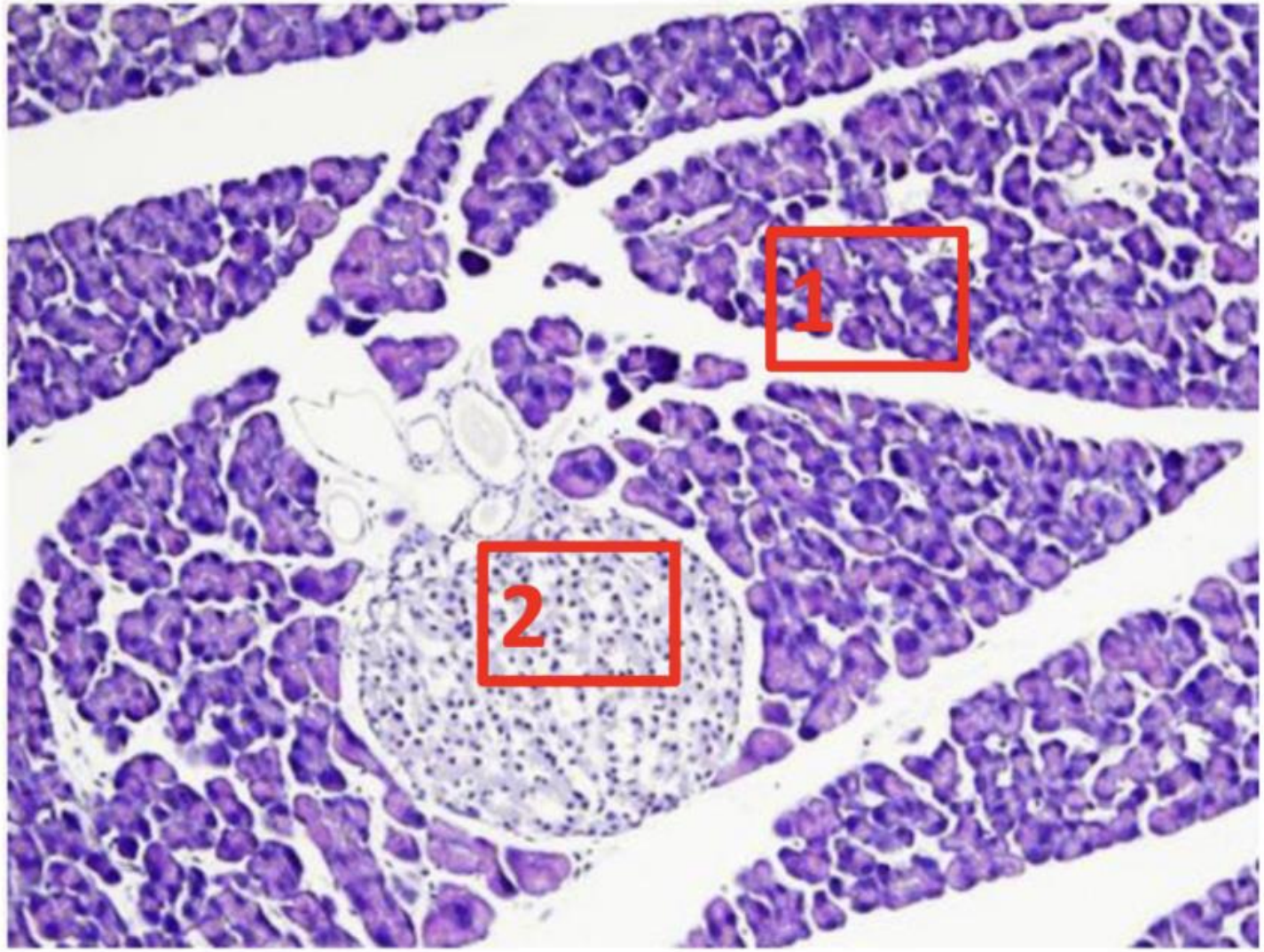

pancreas

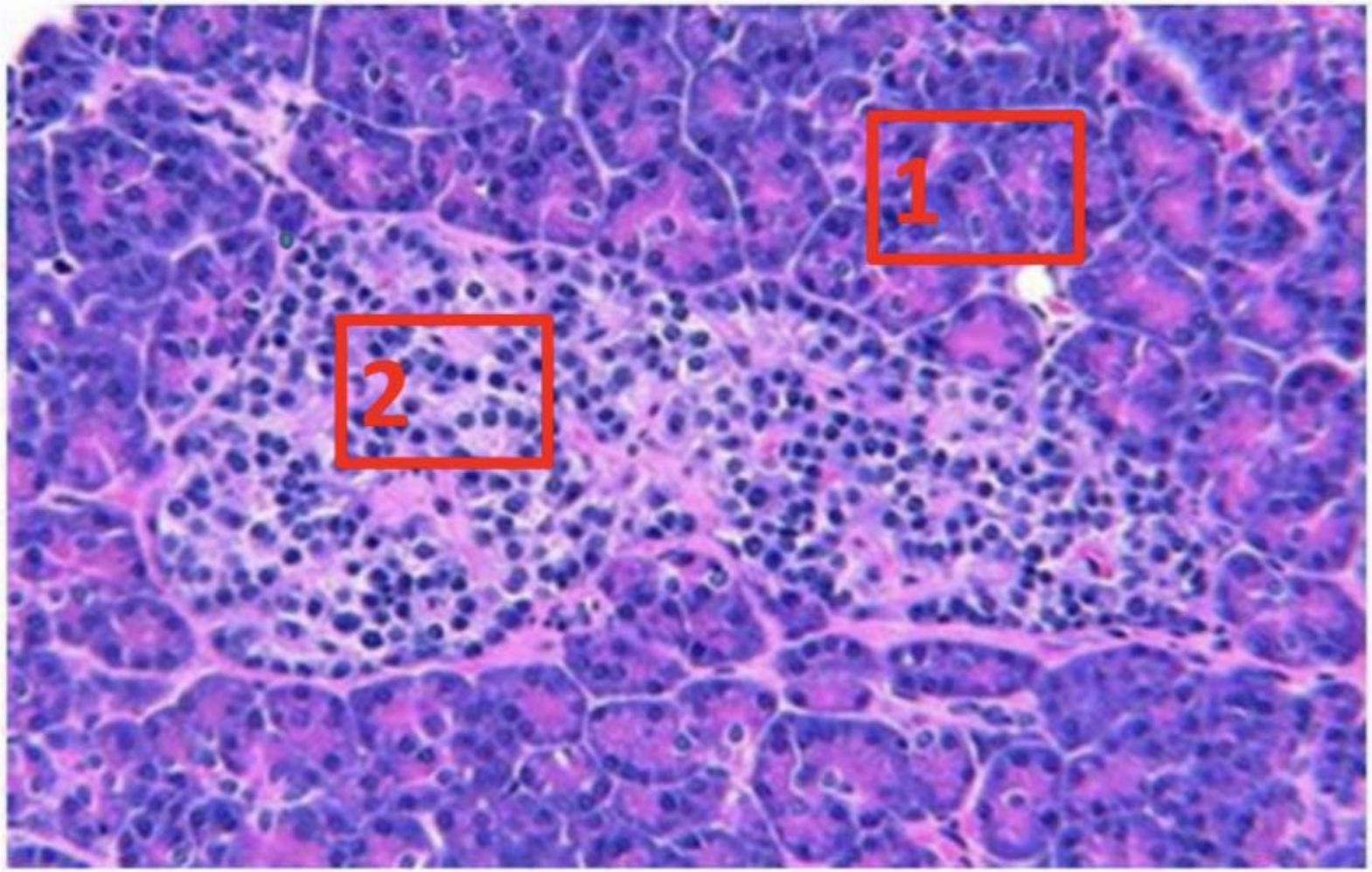

Epithelial cells lining intestinal mucosa :-

Goblet cell

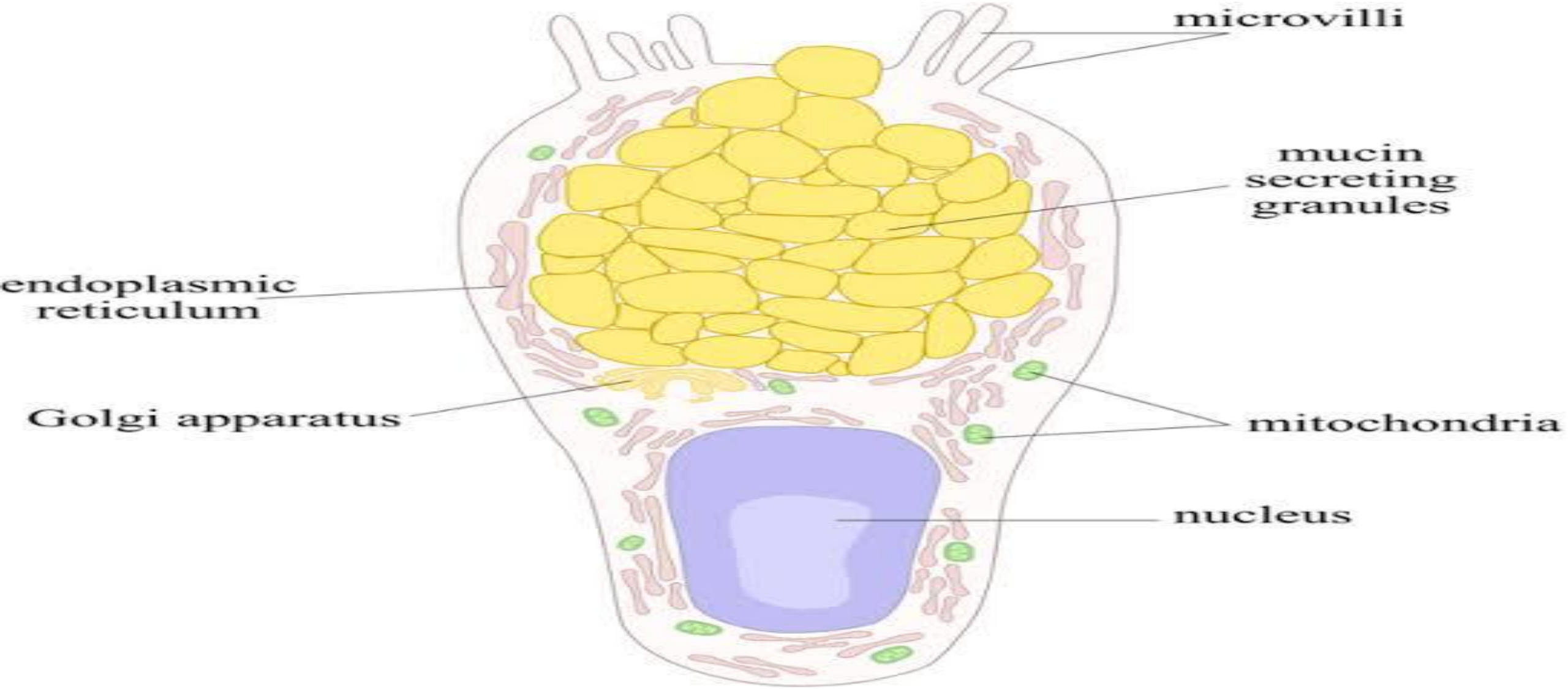
microvilli
mucin secreting granules
endoplasmic reticulum
Golgi apparatus
mitochondria
nucleus

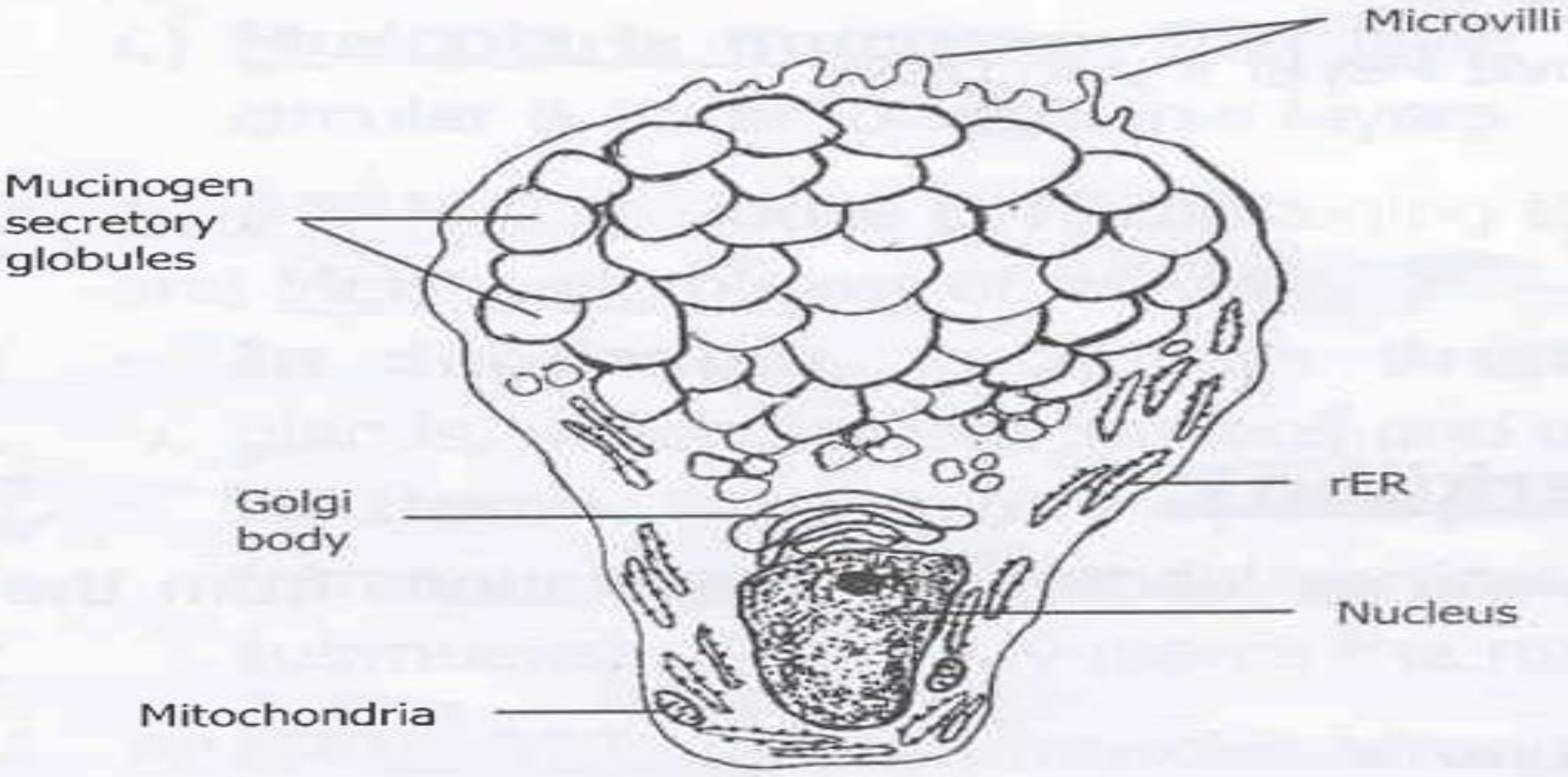
Microvilli
Mucinogen secretory globules
rER
Golgi body
Nucleus
Mitochondria

Goblet cell.

Paneth cell

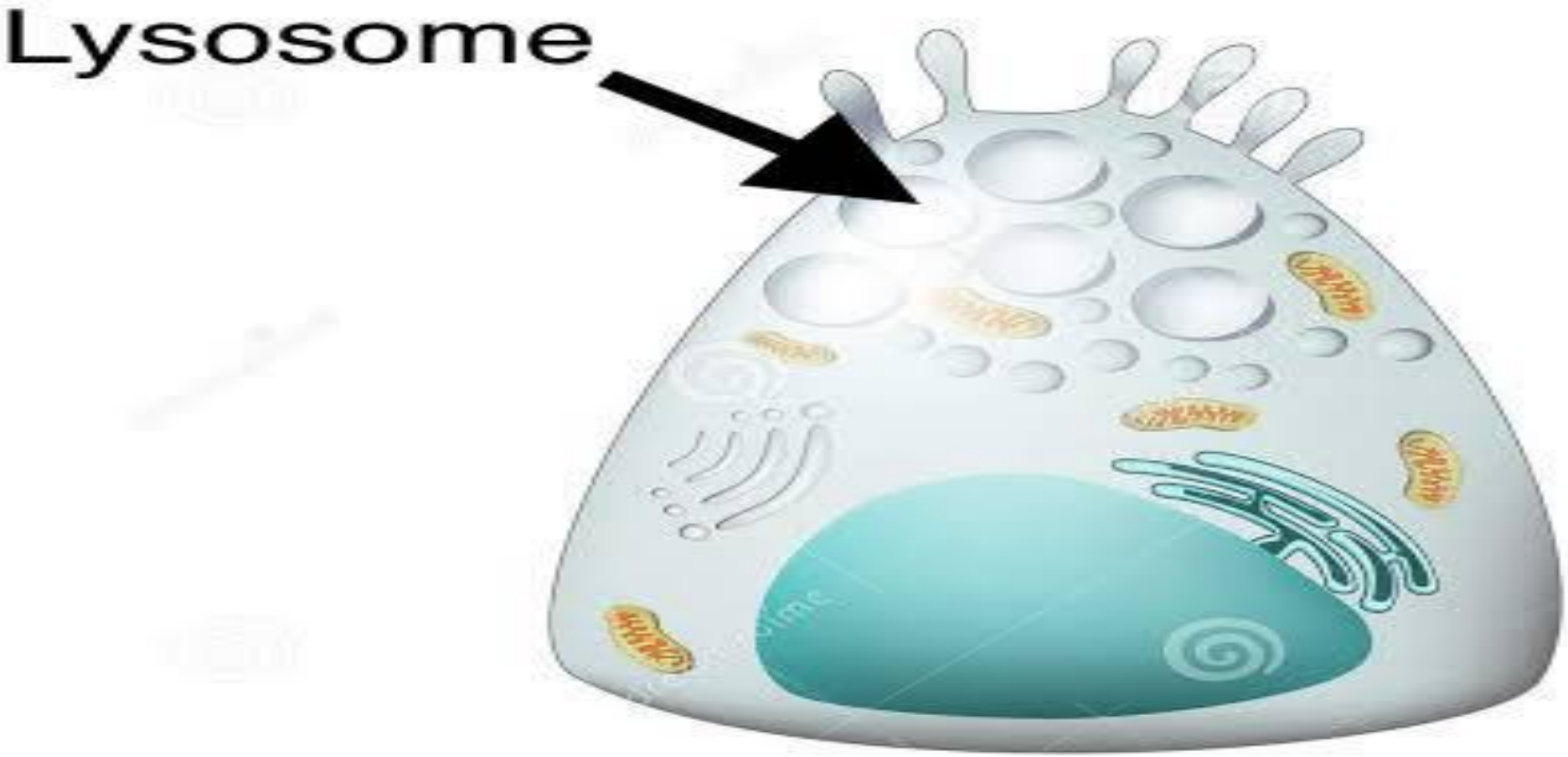

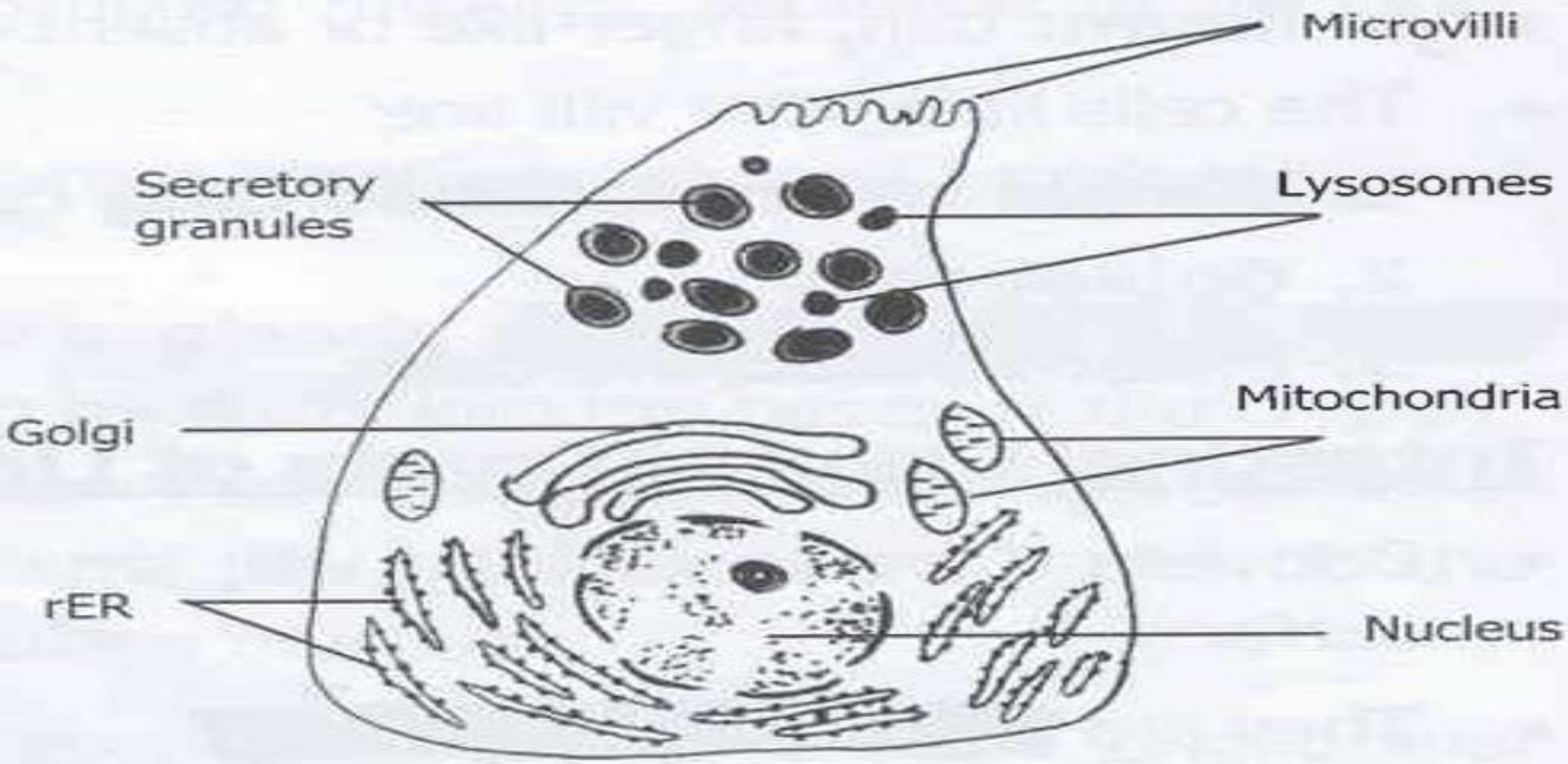
Microvilli
Secretory granules
Lysosomes
Mitochondria
Golgi
rER
Nucleus

Paneth cell.

Absorptive columnar enterocyte

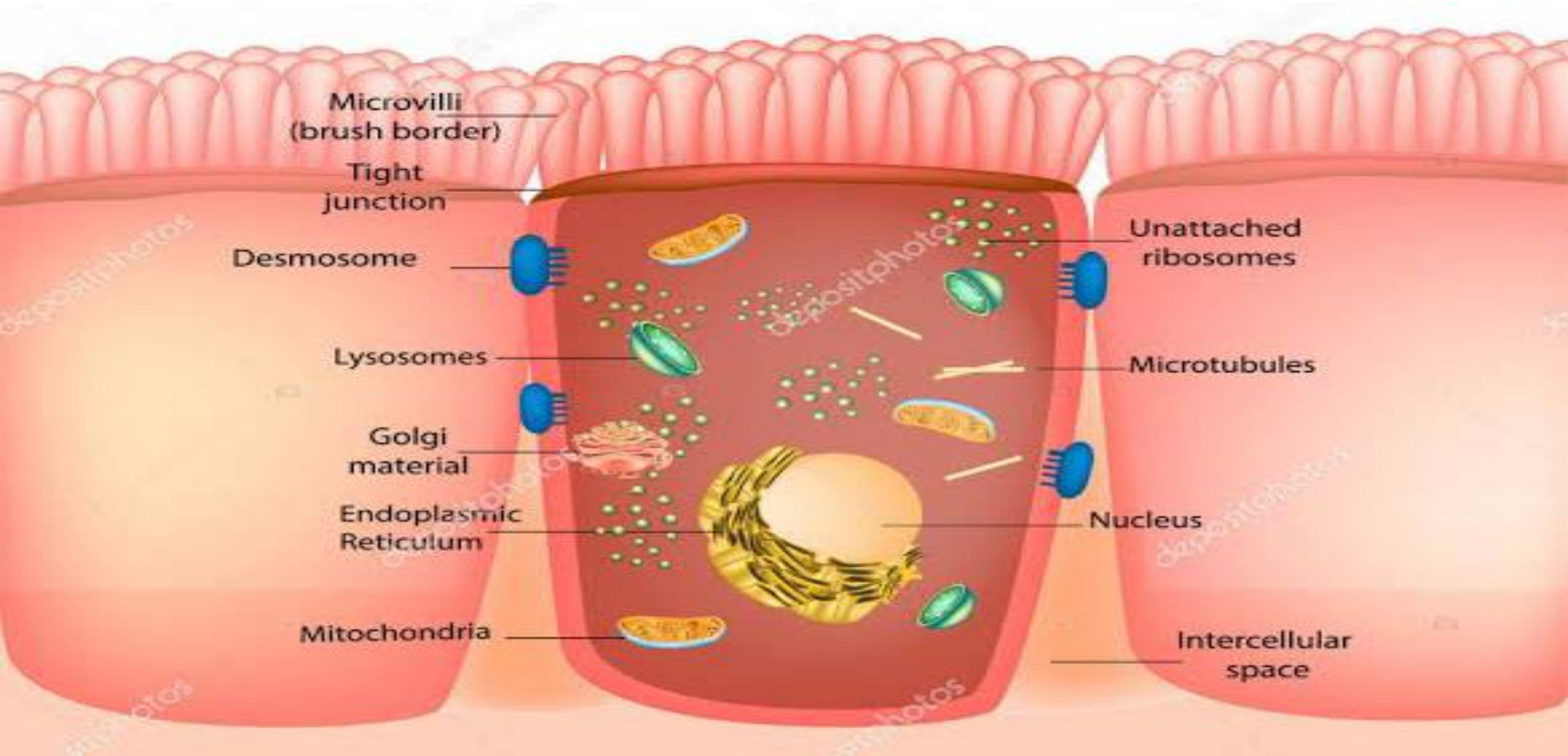

Columnar absorptive cell.

Duodenum

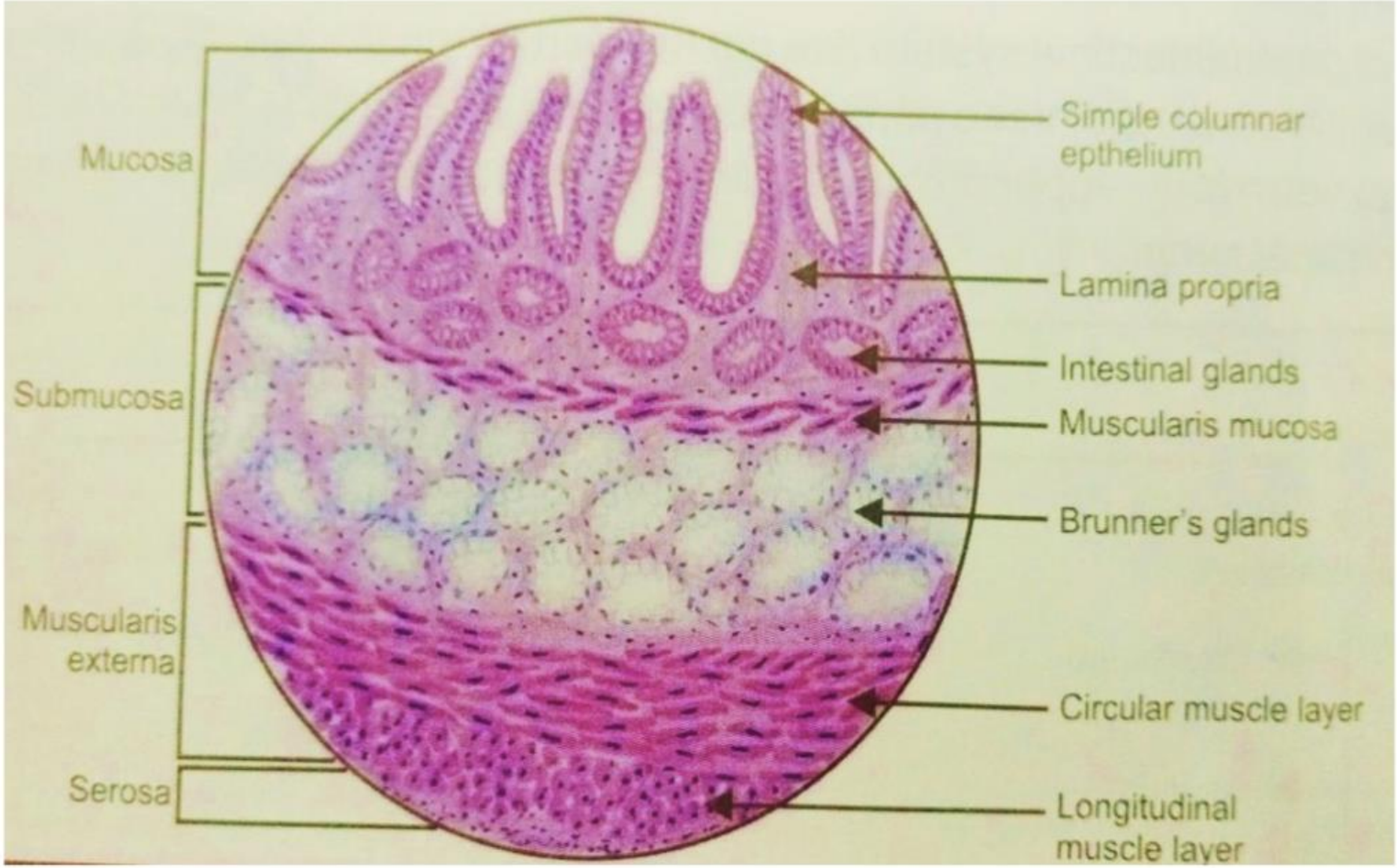
Mucosa
Submucosa
Muscularis externa
Serosa
Simple columnar epthelium
Lamina propria
Intestinal glands
Muscularis mucosa
Brunner's glands
Circular muscle layer
Longitudinal muscle layer

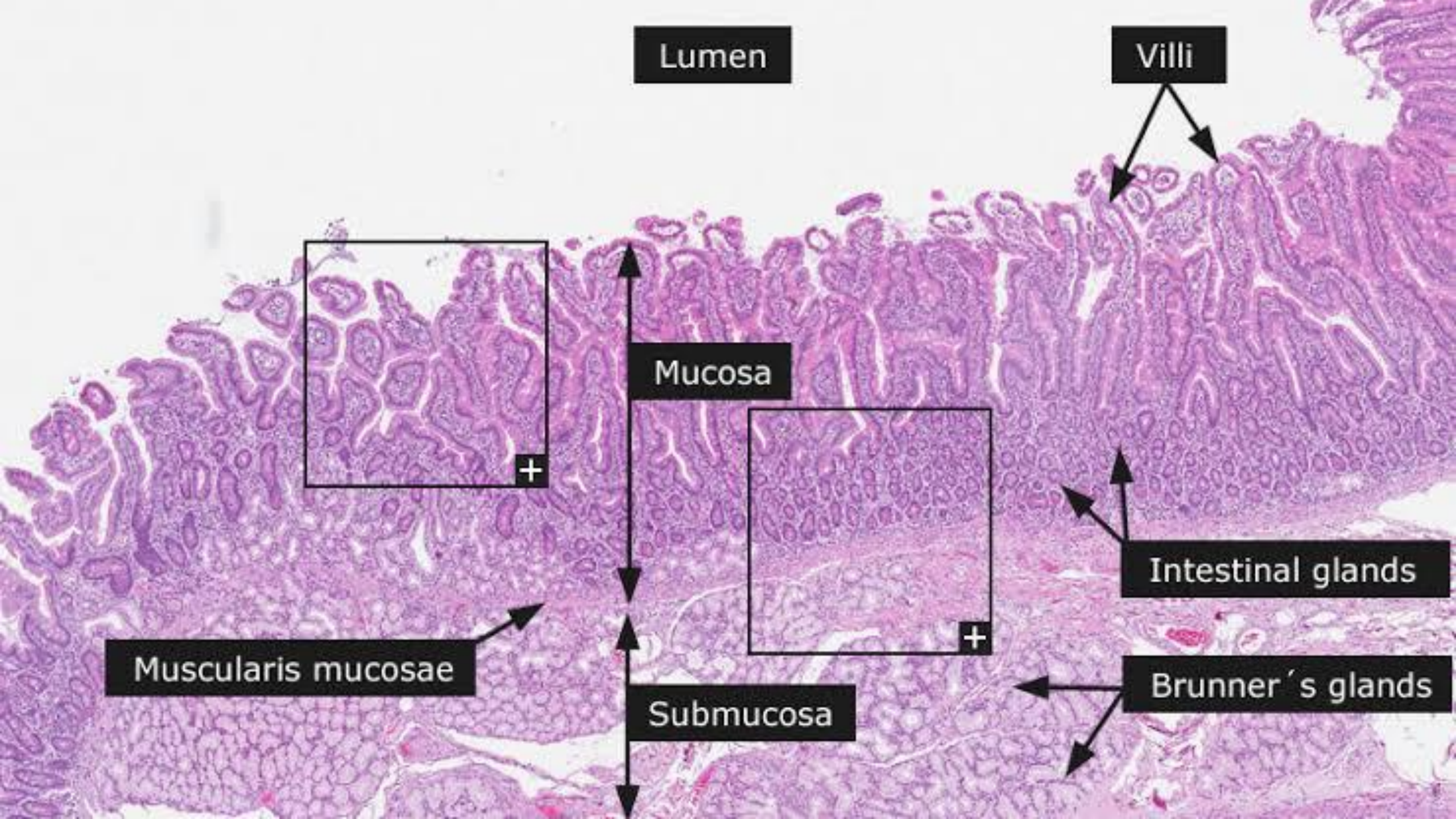
Lumen
Villi
Mucosa
Intestinal glands
Muscularis mucosae
Brunner´s glands
Submucosa

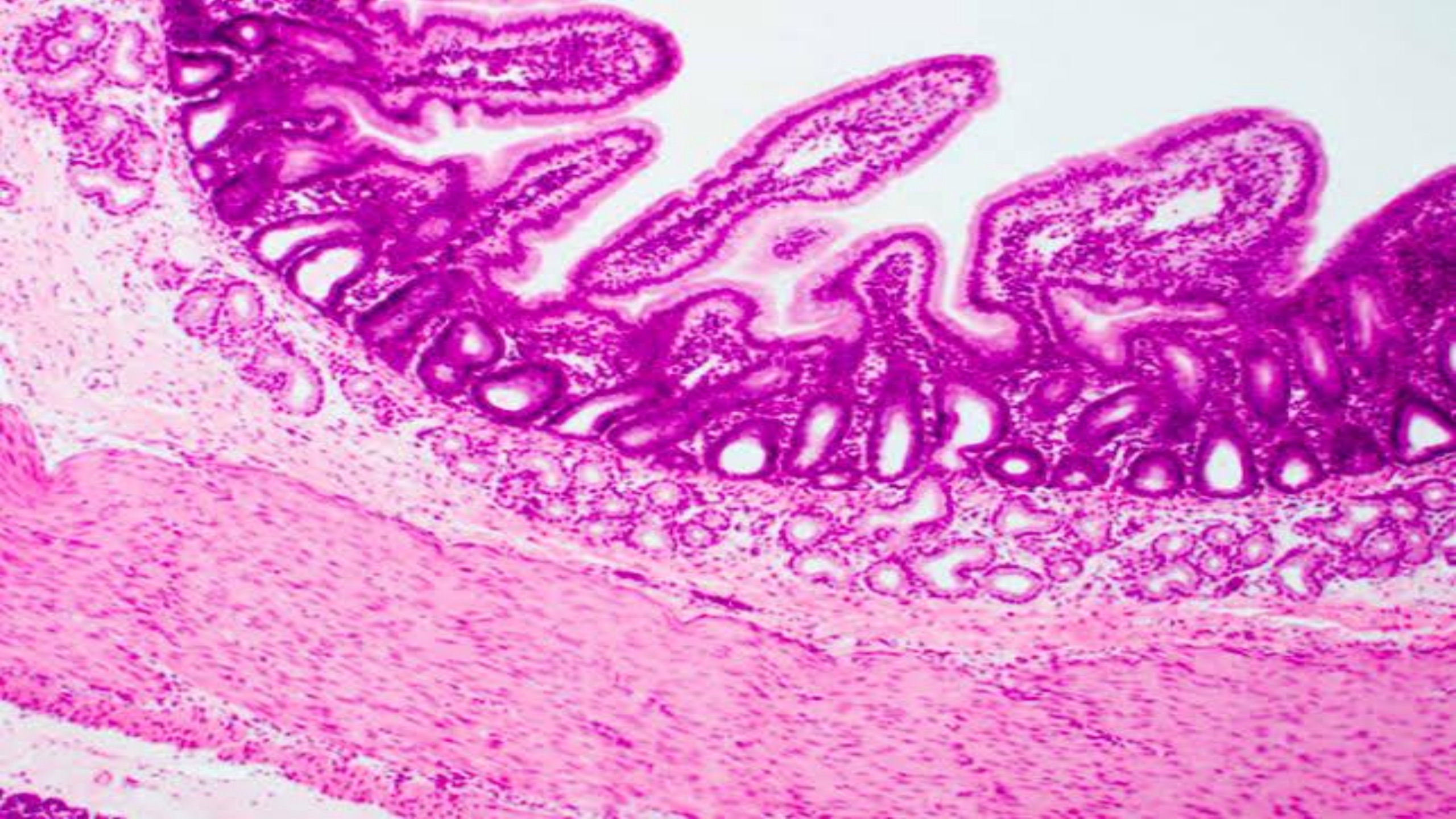

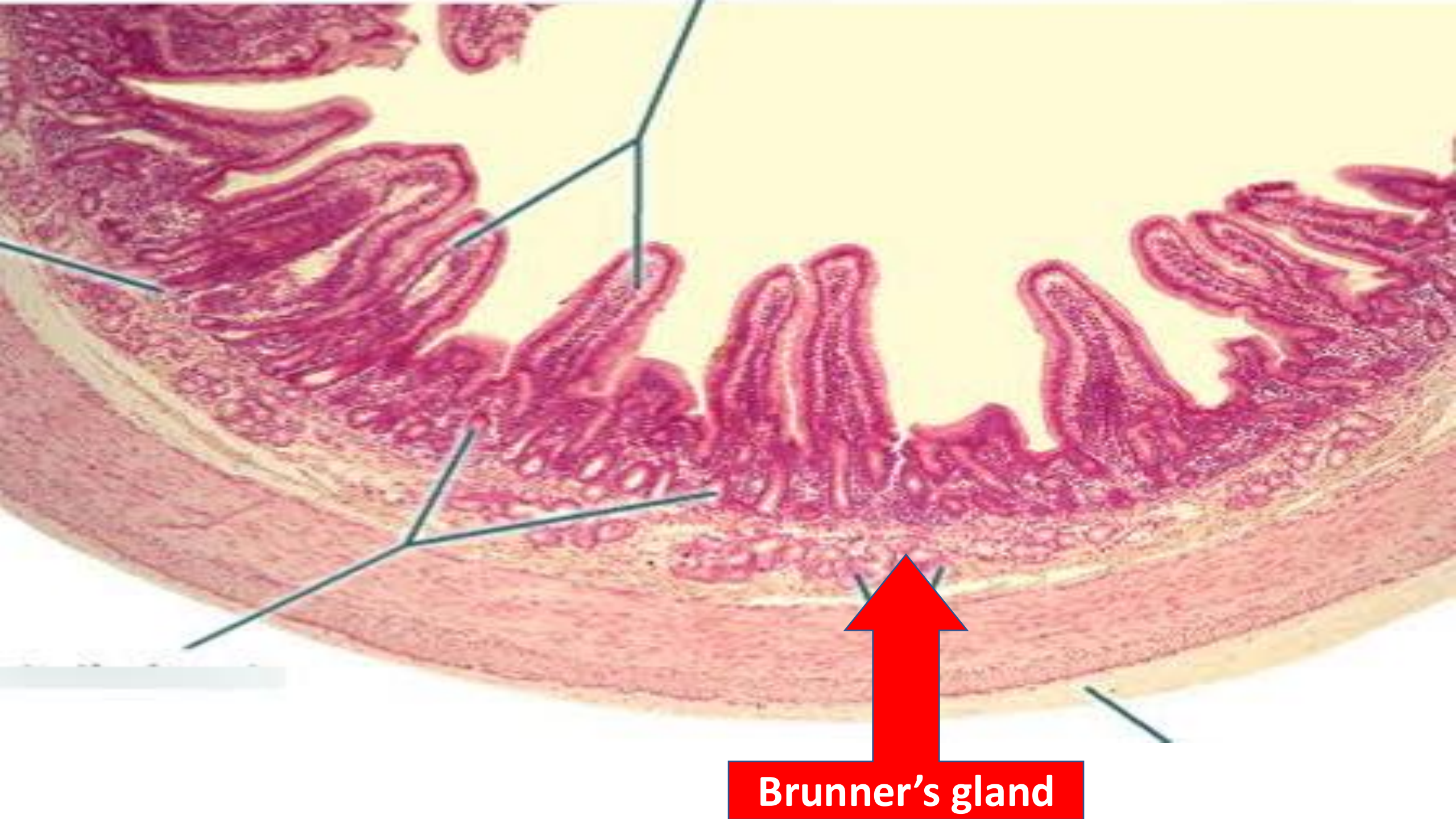
Brunner’s gland

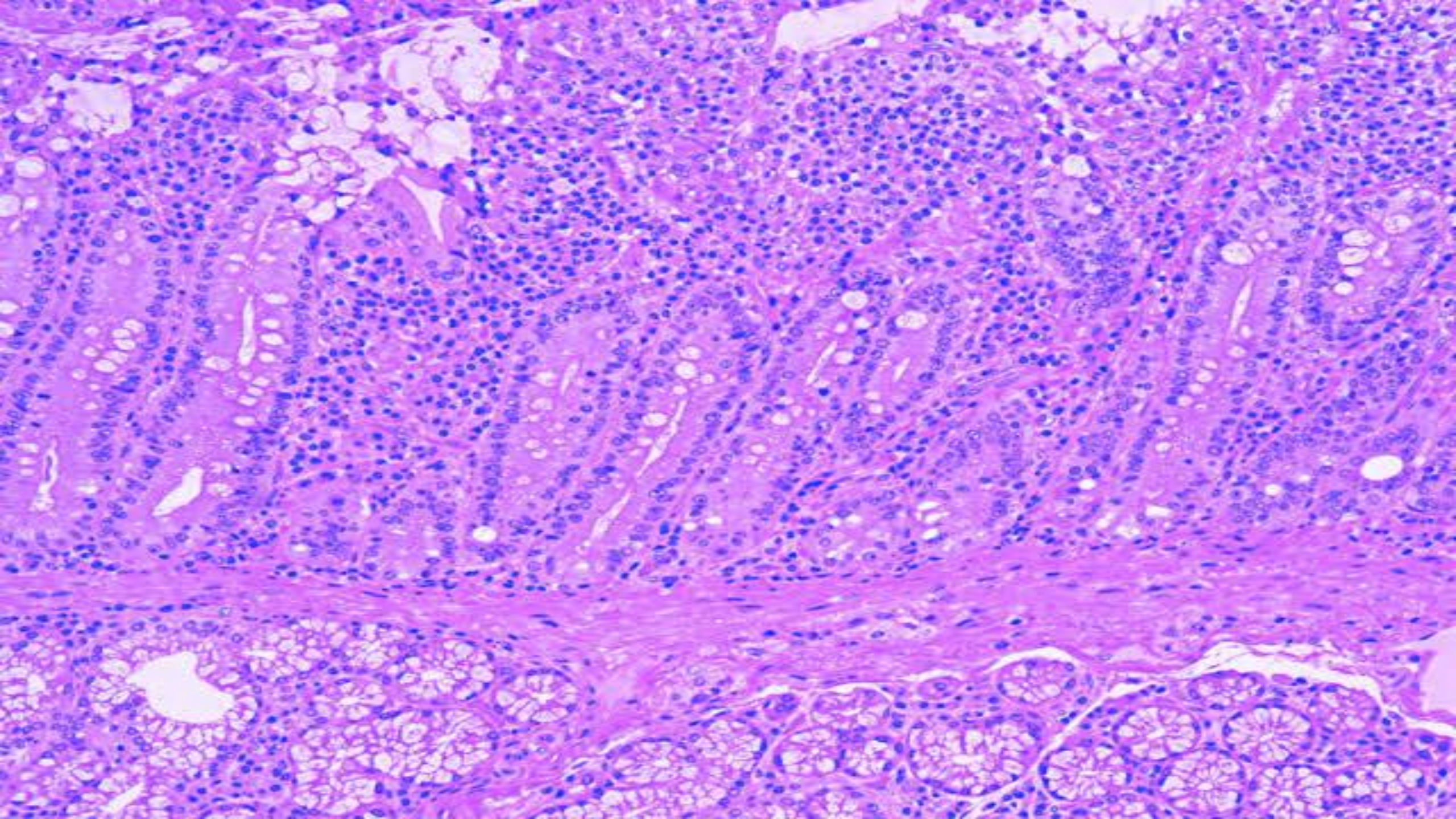

Jejunum

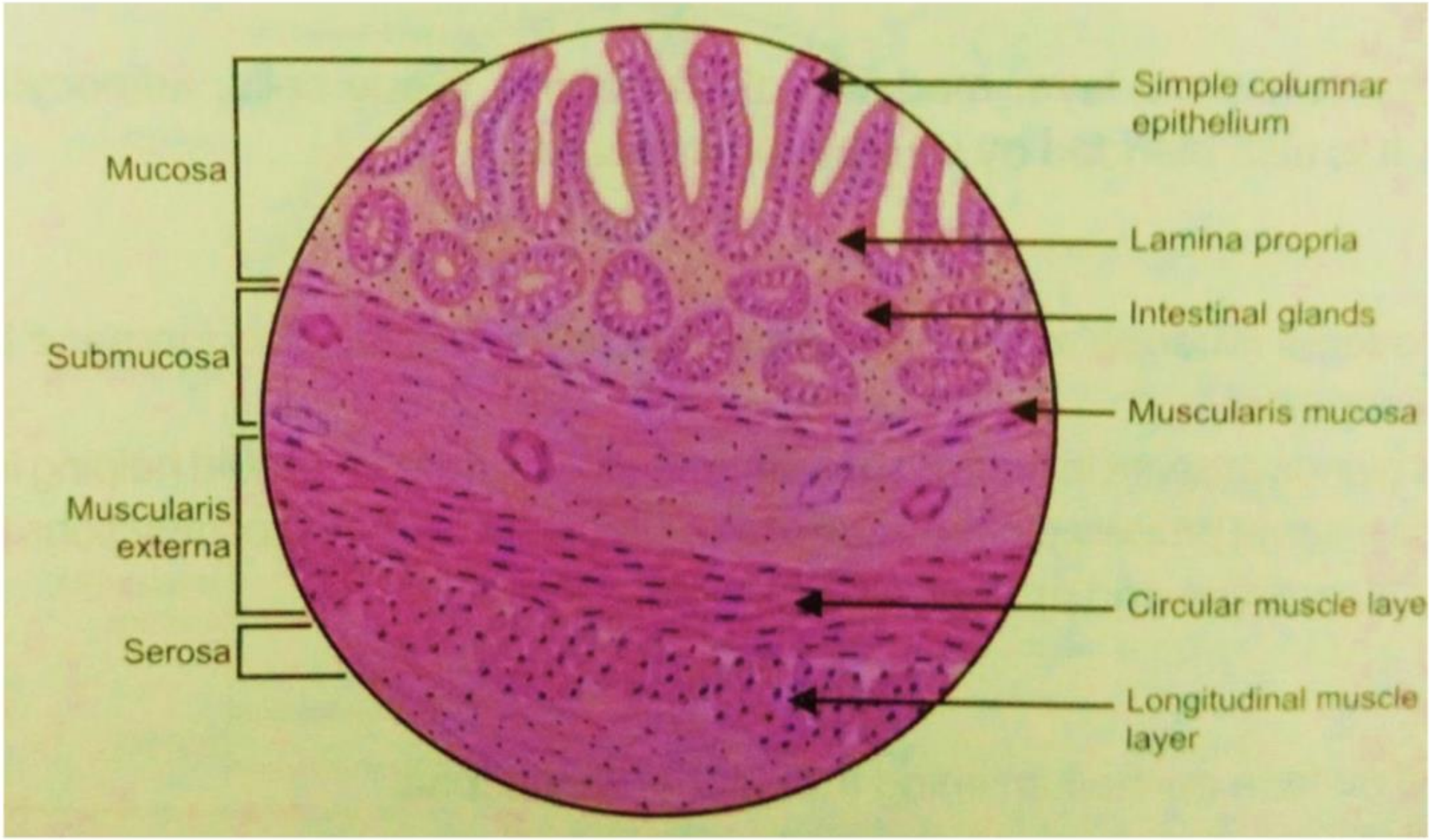
Mucosa
Submucosa
Muscularis externa
Serosa
Simple columnar epithelium
Lamina propria
Intestinal glands
Muscularis mucosa
Circular muscle laye
Longitudinal muscle layer

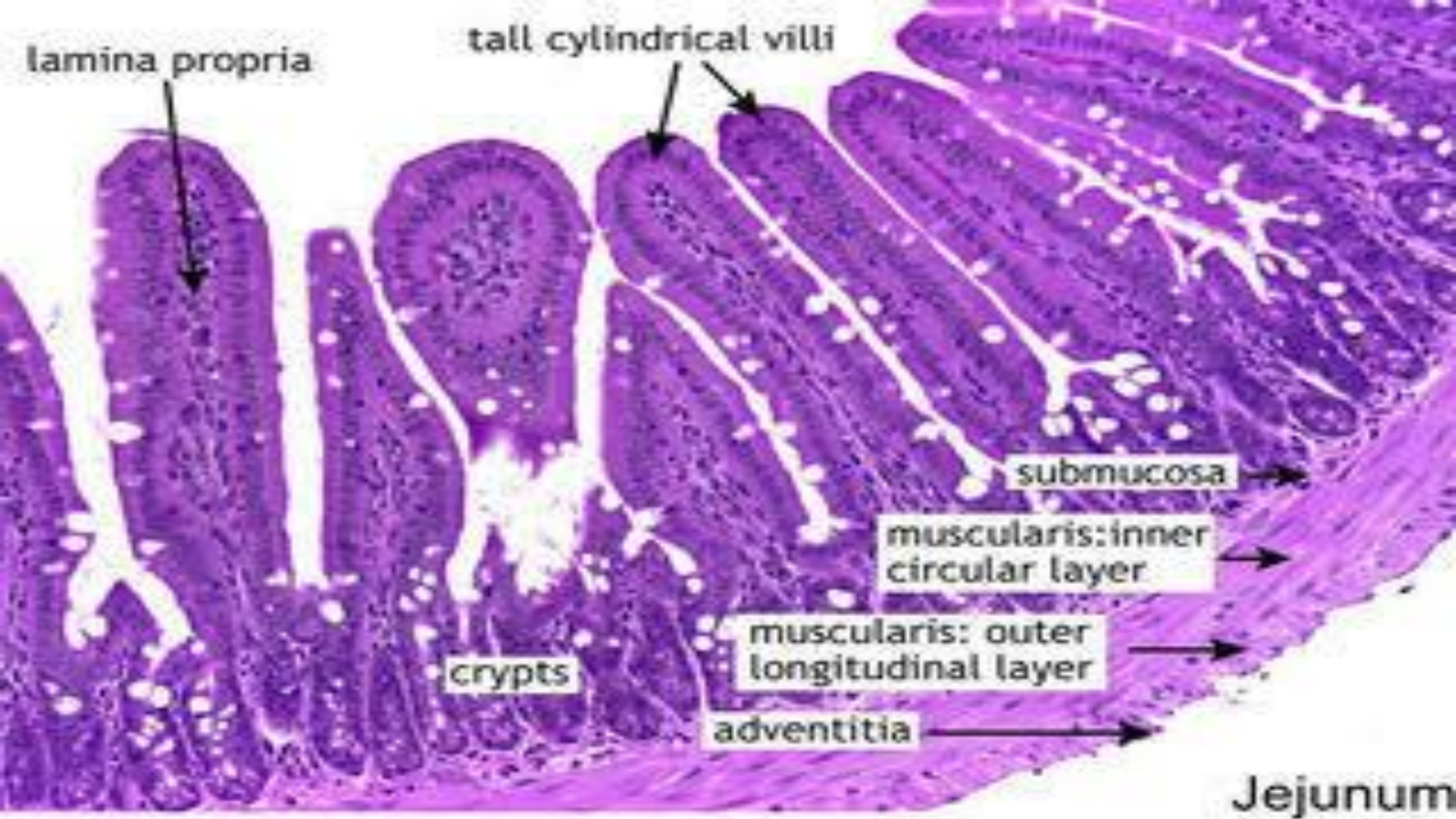
lamina propria
tall cylindrical villi
submucosa
muscularis:inner circular layer
muscularis: outer longitudinal layer
crypts
adventitia
Jejunum

Illeum

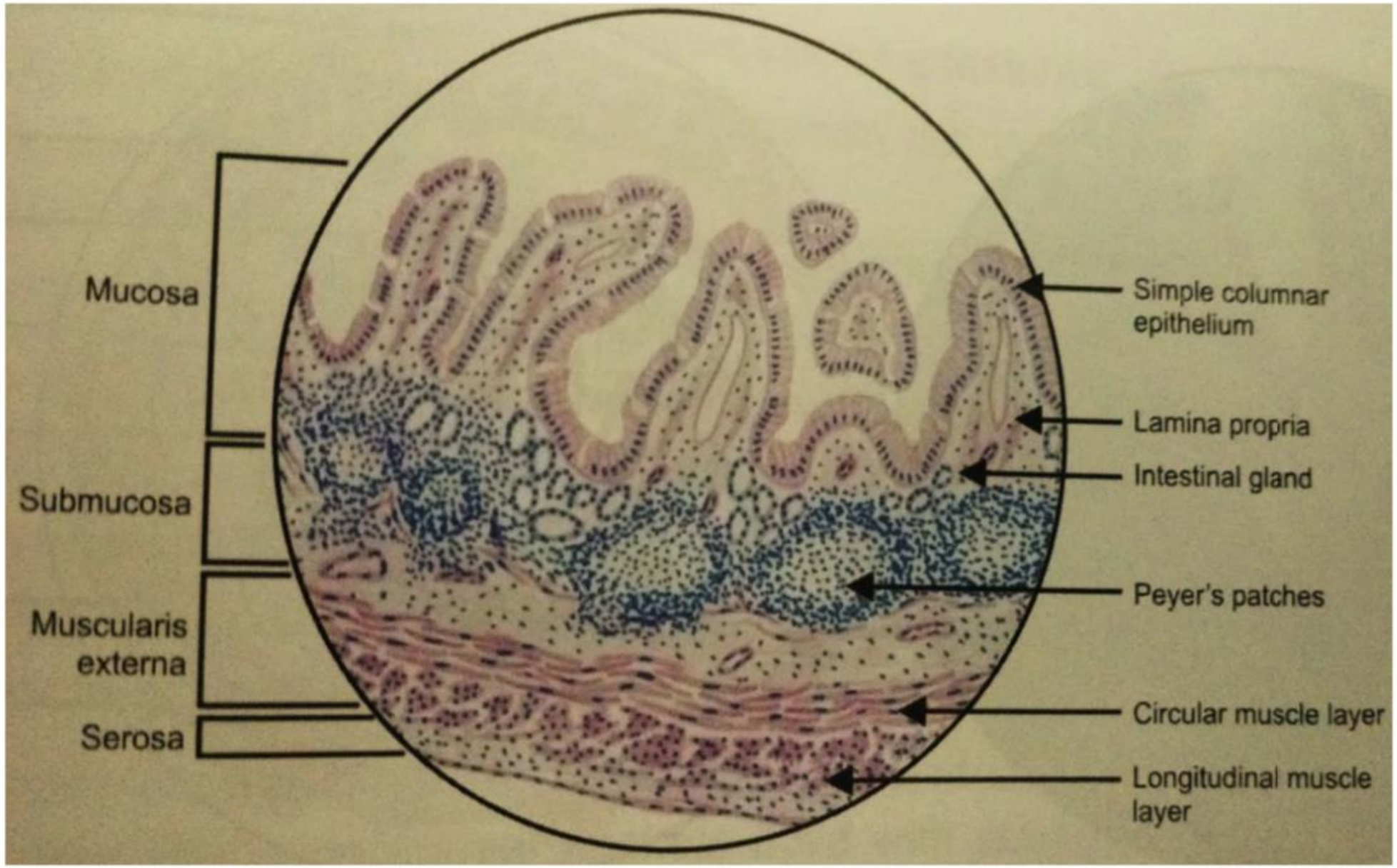
Mucosa
Submucosa
Muscularis externa
Serosa
Simple columnar epithelium
Lamina propria
Intestinal gland
Peyer's patches
Circular muscle layer
Longitudinal muscle layer

Illeum

Type of epithelium: simple columnar with goblet cell

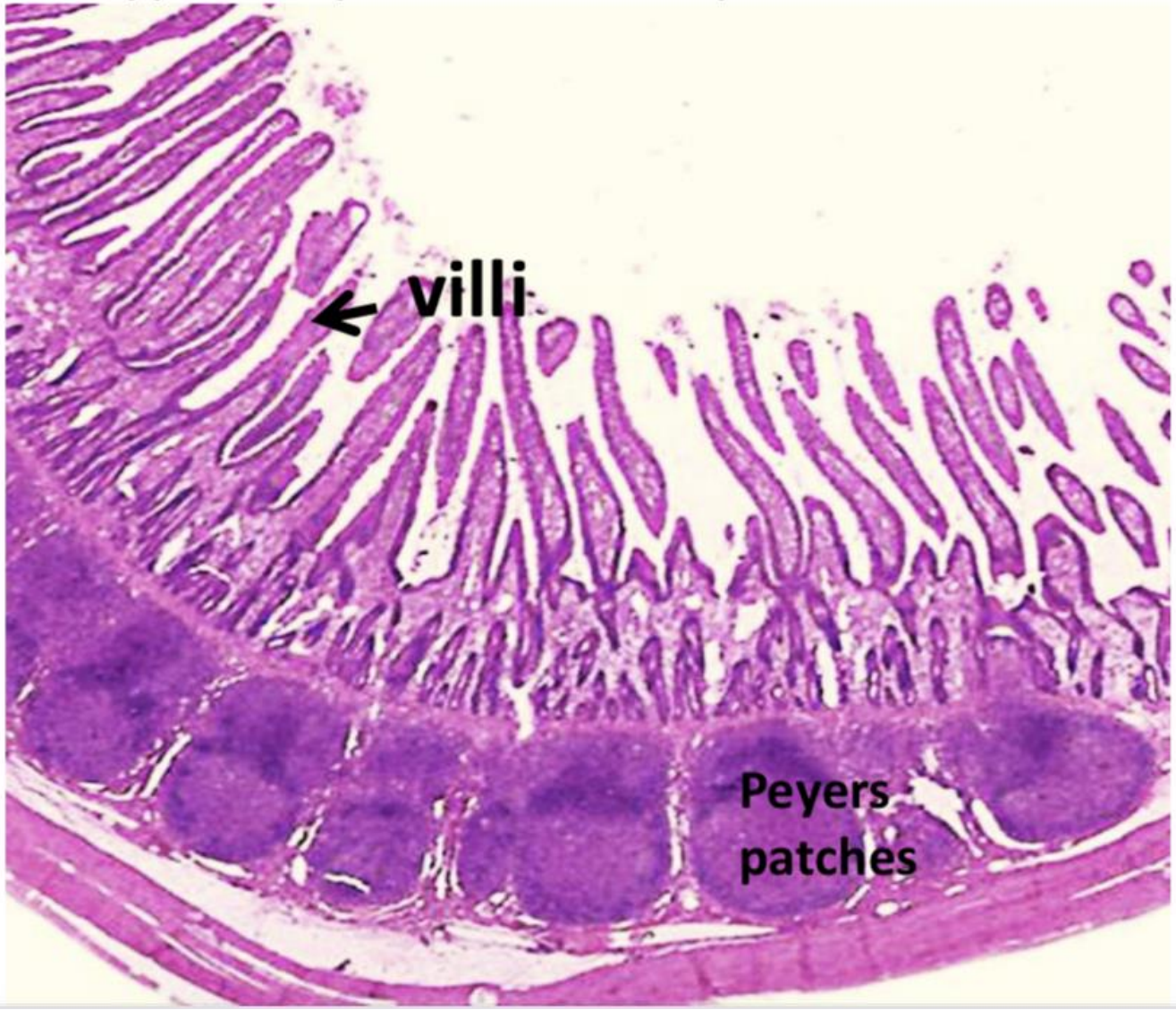

Large intestine (colon)

Type of epithelium: simple columnar with goblet cell

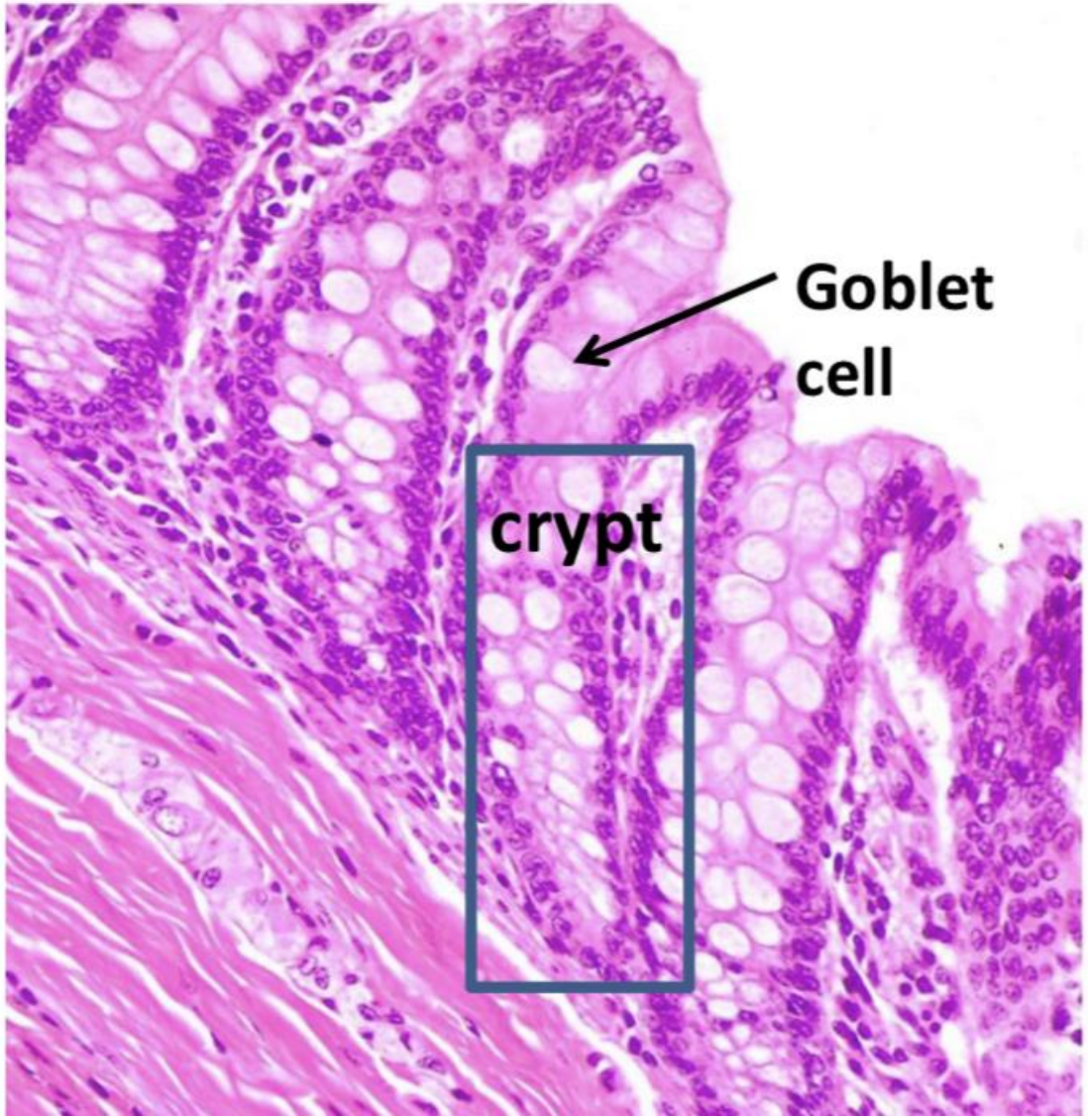

Thank you